

ELECTRON MICROSCOPY OF THE VIRUS OF ORAL PAPILLOMATOSIS IN THE COYOTE

Authors: GREIG, A. S., and CHARLTON, K. M.

Source: Journal of Wildlife Diseases, 9(4) : 359-361

Published By: Wildlife Disease Association

URL: <https://doi.org/10.7589/0090-3558-9.4.359>

The BioOne Digital Library (<https://bioone.org/>) provides worldwide distribution for more than 580 journals and eBooks from BioOne's community of over 150 nonprofit societies, research institutions, and university presses in the biological, ecological, and environmental sciences. The BioOne Digital Library encompasses the flagship aggregation BioOne Complete (<https://bioone.org/subscribe>), the BioOne Complete Archive (<https://bioone.org/archive>), and the BioOne eBooks program offerings ESA eBook Collection (<https://bioone.org/esa-ebooks>) and CSIRO Publishing BioSelect Collection (<https://bioone.org/csiro-ebooks>).

Your use of this PDF, the BioOne Digital Library, and all posted and associated content indicates your acceptance of BioOne's Terms of Use, available at www.bioone.org/terms-of-use.

Usage of BioOne Digital Library content is strictly limited to personal, educational, and non-commercial use. Commercial inquiries or rights and permissions requests should be directed to the individual publisher as copyright holder.

BioOne is an innovative nonprofit that sees sustainable scholarly publishing as an inherently collaborative enterprise connecting authors, nonprofit publishers, academic institutions, research libraries, and research funders in the common goal of maximizing access to critical research.

ELECTRON MICROSCOPY OF THE VIRUS OF ORAL PAPILLOMATOSIS IN THE COYOTE

A. S. GREIG and K. M. CHARLTON¹

Abstract: Electron microscopic examination of an extract of oral papillomas from a coyote revealed a virus morphologically similar to the papovaviruses, consisting of unenveloped, round capsids of cubic symmetry, 47-57 nm in diameter. An accurate count of capsomeres was not possible.

INTRODUCTION

Oral papillomatosis in the coyote has been described in Texas¹ and in Saskatchewan and Alberta.¹ The disease in each case resembled oral papillomatosis in dogs and the histological appearance of the neoplastic tissue was typical of papillomas in general. No mention was made of any attempts to transmit the disease. This is a report of the electron microscopic demonstration of virus in extracts of oral papillomas from a coyote from Manitoba.

MATERIALS AND METHODS

This specimen was received as one of a group of coyote heads submitted for rabies examination. Portions of the papilloma were fixed in buffered 10% formalin, embedded in paraffin, sectioned at 6 μ m and stained with hematoxylin and eosin for examination with a light microscope.

For electron microscopy about 0.5 g of papilloma excised from the lip was ground in distilled water with a Ten Broeck tissue grinder. The suspension was centrifuged at 2000 RPM (800 x g) for 10 minutes and the centrifugate discarded. The supernatant fluid was centrifuged at 30,000 RPM (50,000 x g) for 1 hour and the resulting pellet was re-

suspended in 0.5 ml H₂O. This was given a final centrifugation at 2000 RPM for 10 minutes and the supernatant fluid used for electron microscopy.

Copper grids of 400 mesh, coated with formvar and carbon-stabilized were covered with a drop of the suspension for about 1 minute. This was blotted off by touching the edge of the grids to a piece of bibulous paper. The grids were then covered briefly with 2% potassium phosphotungstate at pH 6.1. They were again blotted, air dried and examined in an RCA EMU 3 (c) microscope at an instrument magnification of 30,000 x.

RESULTS

On gross examination there were numerous papillomas on the surface of the tongue, cheeks and palate and a few on the mucosa of the esophagus (Fig. 1). Histologically in affected areas the epidermis was thickened and folded into many closely packed fronds covered with thickened layers of keratin. Cells of the basal layer retained their polarity. Several cells in the granular layer were swollen and a few contained large magenta intranuclear inclusions.

With the electron microscope, large numbers of round capsids of cubic sym-

¹ Animal Pathology Division, Health of Animals Branch, Canada Department of Agriculture, Animal Diseases Research Institute, P.O. Box 1400, Hull, Quebec, Canada.

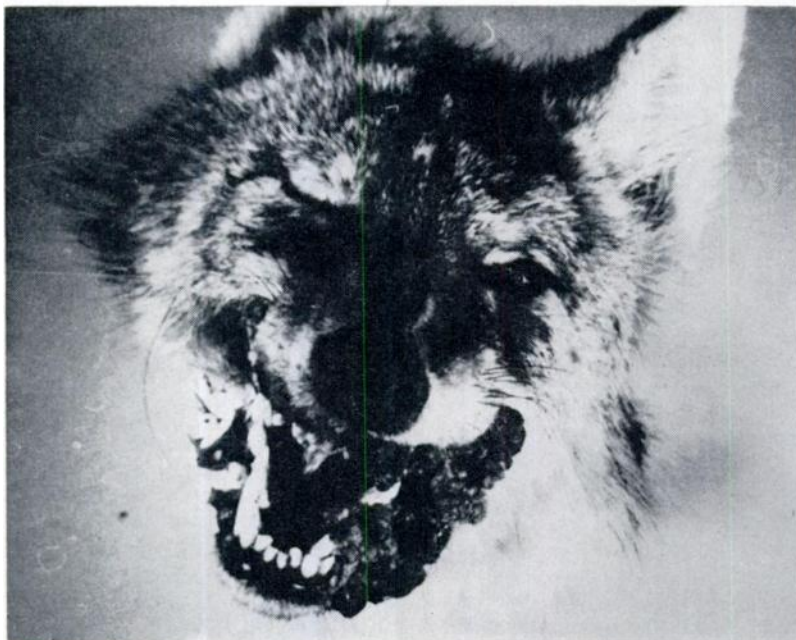


FIGURE 1. Papillomas on the lips and in the mouth of a coyote.

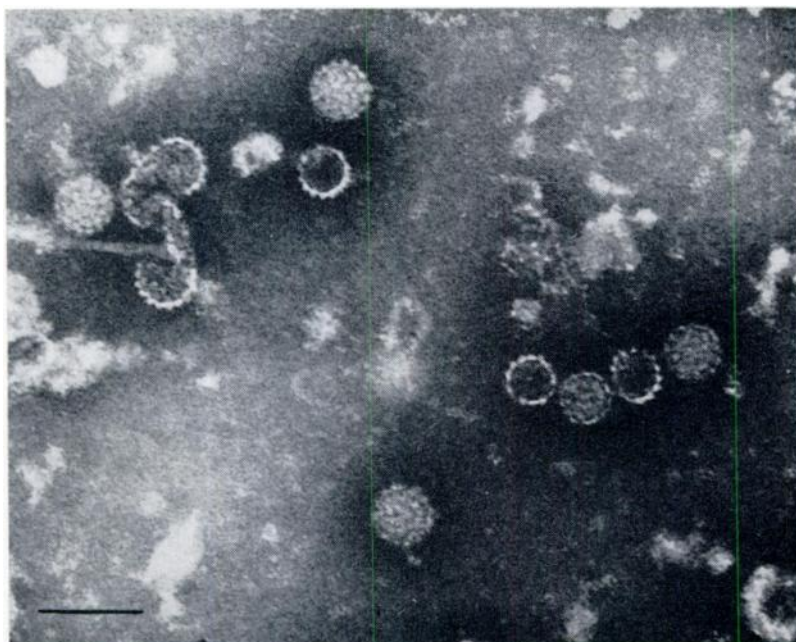


FIGURE 2. Electron micrograph of viral particles from oral papillomas demonstrated by negative contrast stain. Bar = 100 nm.

metry ranging in size from 47 to 57 nm in diameter were seen in all fields. There was no envelope and the capsomeres were prominent. Both "hollow" centre and "full" forms were seen with the latter more numerous. The "hollow" capsids were generally smaller than the "full". An accurate count of the number of capsomeres was not possible. The size, shape and structure of the virions (Fig. 2) were consistent with those features in members of the papovavirus group.³

DISCUSSION

Histologically, oral papillomatosis in the coyote resembles that in the dog and most other species.² The results of this study indicate that ultrastructurally the coyote virus is similar to the papova virus causing canine oral papillomatosis. Since papilloma viruses generally are considered antigenically distinct from one another,³ further studies would be required to demonstrate whether or not the coyote and dog viruses are the same or different.

LITERATURE CITED

1. BROUGHTON, E., F. E. GRAESSER, L. N. CARBYN and L. P. E. CHOQUETTE. 1970. Oral papillomatosis in the coyote in western Canada. *J. Wildl. Dis.* 6: 180-181.
2. CHEVILLE, N. F. and C. OLSON. 1964. Cytology of the canine oral papilloma. *Am. J. Path.* 45: 849-972.
3. MELNICK, J. L. 1962. Papova virus group. *Science*. 135: 1128-1130.
4. TRAINER, D. O., F. F. KNOWLTON and L. KARSTAD. 1968. Oral papillomatosis in the coyote. *Bull. Wildl. Dis. Assoc.* 4: 52-54.

Received for publication 12 June 1973